



ORIGINAL ARTICLE / ОРИГИНАЛНИ РАД

Expression of a fibronectin in the dental pulp of lead intoxicated rats with experimentally induced diabetes mellitus

Irena Kuzmanović-Radman¹, Aleksandra Đeri¹, Radoslav Gajanin², Adriana Arbutina³, Renata Josipović¹, Slavoljub Živković⁴

¹University of Banja Luka, Faculty of Medicine, Department of Oral Diseases, Study Program – Dentistry, Banja Luka, Republic of Srpska, Bosnia and Herzegovina;

²University of Banja Luka, Faculty of Medicine, Department of Pathology, Banja Luka, Republic of Srpska, Bosnia and Herzegovina;

³University of Banja Luka, Faculty of Medicine, Department of Orthodontics, Study Program – Dentistry, Banja Luka, Republic of Srpska, Bosnia and Herzegovina;

⁴University of Belgrade, School of Dental Medicine, Department of Oral Diseases, Belgrade, Serbia

SUMMARY

Introduction/Objective Lead exposure represents one of the most important factors that affect the general health, including oral health and it is associated with enamel and dentin tooth defects.

The aim of this paper was to determine expression of the fibronectin in the pulp of rats with experimentally induced diabetes mellitus (DM), after lead exposure, by using immunohistochemical analysis.

Methods The study was conducted on 42 rats of Wistar strain. Intoxication of rats with lead-acetate was done via drinking water *ad libitum*. The first group (Exp_14) consisted of 16 rats, which received lead in water for 14 days, the second group (Exp_30) consisted of 16 rats which received lead in water for 30 days at the same concentration (1500 ppm), while the control consisted of 10 healthy rats. Groups Exp_14 and Exp_30 were induced into DM, by using the Alloxan intraperitoneally. Pathohistological and immunohistochemical analysis determined fibronectin expression in pulp, odontoblasts, predentin and dentine of the teeth.

Results High diffuse positivity of fibronectin in group Exp_14 was noticed in 63.6% of rats, in group Exp_30 in 24% of rats, while in the control group it was noticed in 50% of rats. There was no statistically significant difference in the expression of fibronectin between the examined groups.

Conclusion Lead intoxication through drinking water, for a period of 14 and 30 days, had effect on the expression of fibronectin in the pulp, odontoblasts, predentin and dentin of the teeth of animals experimentally induced DM.

Keywords: fibronectin; odontogenesis; diabetes; lead

INTRODUCTION

Exposure to lead represents one of the most important health problems because lead affects general health, development of bone and tooth defects and caries formation [1].

Although lead affects the pulp tissue, the number of studies concerning the influence of lead on the reparative dentinogenesis is very limited [1, 2].

Formation of dentin by odontoblasts is a genetically conditioned process involving the whole pulp-dentine complex, but it still represents an insufficiently explained biological phenomenon [2, 3]. During the long-term research the following conclusion has been made: the differentiation of new odontoblasts in the pulp is influenced by numerous factors such as: bone sialoproteins, calcium ions, extracellular matrix, growth factors, fibronectin, tenascin, nerve growth factor from the pulp or cytokines which, through the growth factors, affect the beginning of the formation of reparative dentine [4, 5].

Fibronectin belongs to the class of glycoproteins with high molecular weight and plays an

important role in regulation of cell adhesion, migration and differentiation during developing and reparative processes. Fibronectin surrounds ectomesenchyme cells that polarize and secrete mantle predentin [6].

While the mechanisms of periodontal diseases associated with diabetes mellitus (DM) are largely clarified, cell and molecular mechanisms of dental pulp disorders associated with DM remain unclear. Many studies have shown that the formation of dentine in pathological conditions takes place in genetically predetermined order, depending on the influence of external factors that hinder or stimulate reparative dentinogenesis. It has also been confirmed that the structure of pathological dentine is very similar to the structure of mantle dentin and is most often dependent on the strength and length of irritation [2].

Thaweboon et al. [7] examined the effect of lead on the pulp tissue by observing the cells of the pulp-fibroblast, human teeth *in vitro*. Lead concentration significantly influenced the increased proliferation of the pulp cells and significantly lower protein production, procollagen and osteocalcin [7, 8].

Received • Примљено:
October 22, 2019

Revised • Ревизија:
October 12, 2020

Accepted • Прихваћено:
October 15, 2020

Online first: November 6, 2020

Correspondence to:

Irena KUZMANOVIĆ-RADMAN
Gundulićeva 92
78000 Banja Luka
Republic of Srpska
Bosnia and Herzegovina
irena.radman78@gmail.com

Tziafas et al. [9] in their research explained in more details the structure of pathological dentine i.e., its first layer (crystal zone), osteodentin tissue and tubular dentin, and indicated that in the dentin pulp surrounding the specific stimuli were found: TGF- β 1 and fibronectin that initiate the process of the reparative dentinogenesis.

Wieser et al. [10] in his study also confirmed that fibronectin affects the pulp that differentiates in odontoblasts of a similar cell and that growth factors influence dentinogenesis due to the fibronectin that binds them.

Yoshida et al. [11] examined the distribution of fibronectin in the dental pulp by using indirect immunofluorescence, a confocal laser scanning microscope, and observed the presence of fibronectin in the odontoblastic layer. Leite et al. [12] investigated tenascin-c and fibronectin expression in the pulp after direct calcium hydroxide capping and MTA in permanent teeth of pigs, and noticed that tenascin-C and fibronectin expression in both groups were similar.

DM leads to numerous changes in the human body, mainly in the blood vessels and the nervous system, including oral complications such as pulp microcirculation disorders, slowing down its metabolism, and thus the odontogenesis process [12, 13].

The aim of this paper was to use immunohistochemical analysis to determine the expression of fibronectin odontogenesis mediator in the dental pulp of rats with experimentally induced DM, after the exposure to the lead.

METHODS

The research was conducted after the approval of the Ethics Committee of the University Clinical Center in Banja Luka no. 01-9-192.2 /15, Bosnia and Herzegovina. The sample consisted of 42 Wistar rats.

The animals were two months old with a body weight of 150–200 g and were kept under special conditions. Rats were kept in group plexiglass cages, at 12 hours of light regime (07.00–19:00) at an air temperature of 22°C (\pm 2) and humidity of 60% \pm 10%, where they had free access to food and water during the experiment. At the beginning of the experiment, the individuals were separated into appropriate test and control groups. They were given a 15-day adaptation period, after which the treatment began. For immunohistochemical analysis, thin sections of dental pulp soft tissue were collected on positively charged Super Frost slides (Menzel-glaser), after which tissue sections were deparaffinized, rehydrated, and stained by blocking endogenous peroxidase activity. The reaction was performed by incubating the tissue in 3% hydrogen peroxide solution for 10 minutes at room temperature and then the hydrogen peroxide was washed with distilled water, and the procedure was continued by enzymatic unmasking of the target antigens. The enzyme trypsin (Thermo Fisher Scientific Fremont, Waltham, MA, USA) was used for unmasking. Enzyme digestion was being performed for 10 minutes at room temperature. Then tissue sections were washed with distilled water and TBS buffer (Tris buffered saline) pH 7,4 and treated with commercial solutions to block nonspecific

reactions: Rodent Block R (Biocare Medical, Concord, CA, USA) for fibronectin.

On the tissues prepared in this way, immunohistochemical detection of the target antigen was performed by horseradish peroxidase reaction using rabbit polyclonal Anti-Fibronectin antibody (Rabbit polyclonal Anti-Fibronectin antibody, PA1-23693, Thermo Fisher Scientific, Waltham, MA, USA). The optimally diluted antibody was applied to the tissues and allowed to stand overnight in the refrigerator at 4°C. After incubation, the next day the excess antibody was washed with TBS buffer (Tris buffered saline) pH 7,4.

EnVision + Single Reagents /HRP Rabbit (Dako Corporation, Carpinteria, CA, USA) was used to visualize fibronectin. The incubation of the polymer system lasted 30 minutes. It was performed at room temperature in a humid chamber, after which the tissues were washed with TBS buffer. Specific immunostaining became visible after five minutes of incubation with 3,3'-diaminobenzidine tetrahydrochloride chromogen (DAB chromogen). After washing the excess chromogen to show the complete tissue structure, the tissue sections were contrasted with Mayer's Hematoxylin (30 seconds), washed with water, dehydrated in increasing ethanol concentration (70%, 90%, and 100%), clarified in xylene and permanently incorporated into Canada balsam. After that, the finished preparations were analyzed on a Leica DM2000 light microscope and photographed with a camera connected to a microscope.

The rats were divided into two experimental groups (Exp_14 and Exp_30) and one control group (control). The first (Exp_14) group consisted of 16 rats (256 molars and premolars of the upper and lower jaw) with experimentally-induced DM that received lead in water in the course of 14 days at a concentration of 1500 ppm. The second (Exp_30) group consisted of 16 rats (256 molars and premolars of the upper and lower jaw) with experimentally-induced DM that received lead in water in the course of 30 days at a concentration of 1500 ppm. The control consisted of 10 healthy rats.

In the rats of the first and the second group (Exp_14 and Exp_30) body weight and the level of blood sugar had been recorded before the experiment started. Using Alloxan the first and second group of rats (Exp_14 and Exp_30) were brought into experimentally induced DM. Alloxan solution was administered intraperitoneally at a dose of 100 mg per kilogram of body weight of the rats. The protocol was repeated every other day until the measured glycemic values exceeded 200 mg/dcl. Glycemia was measured using a device for glycemia measurement (ACCU ACEH, Roche, Basel, Switzerland) from the blood of the tail vein.

Protocol for lead intoxication

Intoxication of adult rats with lead-acetate at a concentration of 1500 ppm was performed via drinking water *ad libitum*. Lead intoxication lasted 14 days in Exp_14, and 30 days in Exp_30. All the procedures performed on animals were done in accordance with the Guide for the Care and Use of Laboratory Animals [14]. After the period determined for intoxication by lead, animals were sacrificed and the upper

and lower jawbones were separated from the soft tissues and stored in the fixative (10% neutral buffered formalin).

In the laboratory of the Department of Pathology of the University Clinical Center Banja Luka preparation for pathohistological and immunohistochemical analysis was performed. The tooth samples were painted by using standard hematoxylin–eosin (HE) method and analyzed by using a light microscope (Leica DM2500, Leica Biosystems, Wetzlar, Germany).

On prepared dental pulp tissues, the immunohistochemical detection of targeted antigens was performed using the reaction of horseradish peroxidase applying Rabbit polyclonal Anti-Fibronectin antibody (Rabbit polyclonal Anti-Fibronectin antibody, PA1-23693, Thermo Fischer Scientific Waltham, MA, USA). For visualization of fibronectin, EnVision + Single Reagents / HRPRabbit (Dako Corporation, Carpinteria, CA, USA) was used. Final preparations were analyzed using light microscopy Leica DM2500

Expression was determined in the pulp (loose connective tissue of the pulp, pulp fibroblasts), odontoblasts, predentin and dentin (odontoblast extensions – Tomes' fibers located in predentin and dentin). The expression estimation of the examined antibodies was performed in accordance with personal semi-quantitative scale (Table 1).

Table 1. Criteria used for semi-quantification of expression

Grade	Parameter
0	Absence of staining, all analyzed structures without staining
1	Weak or moderate, focal positivity / diffuse weak positivity
2	High focal positivity / diffuse moderate positivity
3	Diffuse high positivity

Statistical analysis

The statistical analysis was done by using the IBM SPSS20. The following descriptive statistical parameters were determined: frequency, percentage, arithmetic mean, standard deviation, median, minimum and maximum. A χ^2 test was used as the analytical statistical method ($\alpha = 0.05$).

RESULTS

The results of immunohistochemical analysis are shown in Table 2 and Figures 1, 2, and 3.

In the first experimental group (Exp_14), high diffuse positivity of fibronectin (grade 3) was noted in 63.6% of the cases (Figure 1), high focal positivity (grade 2) in 27.3% of

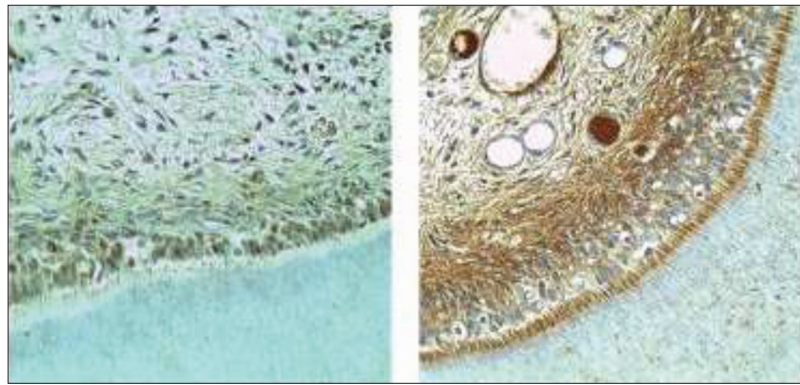


Figure 1. Cross section of the teeth of rats which received lead in the course of 14 days: a) representation of moderate expression (grade 2) of fibronectin in cytoplasm of odontoblast (400 \times); b) representation of high expression (grade 3) of fibronectin in cytoplasm of odontoblast (400 \times)

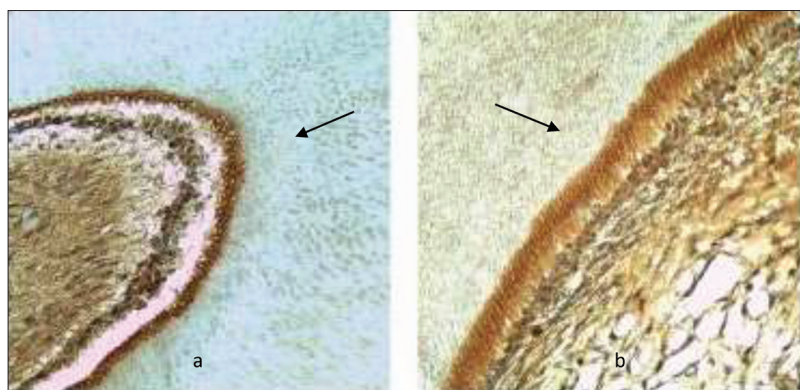

Figure 2. Cross section of the teeth of rats which received lead in the course of 30 days: a) representation of high expression (grade 3) of fibronectin in cytoplasm of odontoblast (200 \times); b) representation of high expression (grade 3) of fibronectin in cytoplasm of odontoblast 400 \times)

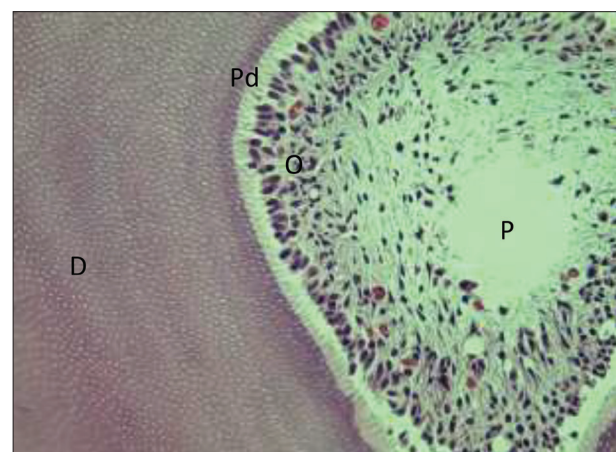

Figure 3. Tooth cross section – control group; pulp, odontoblast layer, predentin, and dentin without morphological changes can be seen (H&E, 400 \times); P – pulp; O – odontoblast layer; Pd – predentin D – dentin

the cases, weak or moderate (grade 1) in 9.1% of the cases while absence of staining (grade 0) was not registered in either case (Table 2).

In the second experimental group (Exp_30), high diffuse positivity of fibronectin (grade 3) was noted in 24% of the cases (Figure 2), high focal positivity (grade 2) in 48% of the cases, weak or moderate (grade 1) in 24% of

Table 2. Expression of fibronectin in the study groups

Study groups			Fibronectin expression				Total
			Absence of staining	Weak or moderate focal positivity	High focal positivity	High diffuse positivity	
Group	Pb 14 days	n	0	1	3	7	11
		%	0%	9.1%	27.3%	63.6%	100%
	Pb 30 days	n	1	6	12	6	25
		%	4%	24%	48%	24%	100%
	Control	n	0	1	5	6	12
		%	0%	8.3%	41.7%	50%	100%
Total	n	1	8	20	19	48	
	%	2.1%	16.7%	41.7%	39.6%	100%	

There was no statistically significant difference in the expression of fibronectin between tested groups ($\chi^2 = 6.864$; $p = 0.345$)

the cases, while the absence of staining was registered in one case (Table 2).

In the control group in healthy rats (without hyperglycemia and without lead intoxication) high diffuse positivity of fibronectin (grade 3) was noted in 50% of the cases (Figure 3), high focal positivity (grade 2) in 41.7% of the cases, weak or moderate (grade 1) in 8.3% of the cases, while the absence of staining was not registered in either case. There was no statistically significant difference in the expression of fibronectin among the examined groups ($\chi^2 = 6.864$, $p = 0.345$) (Table 2).

DISCUSSION

DM is a condition of chronic hyperglycemia and predisposing factor for caries, enamel hypoplasia in infants from mothers with diabetes, gingivitis, periodontitis, oral candidiasis, xerostomia and many other oral cavity diseases [15, 16, 17].

Fibronectin represents one of the most significant glycoproteins which has a major influence on the odontogenesis process. It maintains the connection between cells and components of the extracellular matrix in healthy and infected tissues; affects the migration and polarization of odontoblasts and is considered to be a trigger for differentiation of odontoblasts [18–21].

The results of this study have shown that high diffuse expression of fibronectin was the largest in the group of teeth which belonged to the rats with experimentally induced DM that were intoxicated with lead through water in the course of 14 days. High focal expression of fibronectin was the highest in the group of teeth of rats that were intoxicated with lead in the course of 30 days.

These results can be explained by the fact that the group of rats (Exp_14) received lead through drinking water in a shorter period than the other group (Exp_30) which at a different level stimulated the reparative dentinogenesis i.e., fibronectin expression. Reduced expression of fibronectin of high diffuse positivity in the group of rats that were intoxicated with lead in the course of 30 days could be related to the fact that in the case of prolonged hyperglycemia and lead intoxication, the odontogenesis process was modified. Previous studies confirmed that there were changes in the small and large blood vessels in the dental pulp of rats

with DM, especially the basement membrane thickening, which affects the leukotaxis of polymorphonuclear leukocytes and cellular immune system elements. These changes are most pronounced in the central zone of pulp which could be the reason for the confirmed low expression of fibronectin of high diffuse positivity in the second group of rats in this study [12, 22, 23].

High expression of fibronectin was noted in pulp cells after non-specific inductive effects of certain factors, such as bacterial and mechanical

factors, on the pulp resulting in the formation of a fibronectin-rich matrix. This matrix serves as a source of growth factors, which are considered to be signaling molecules for odontoblast differentiation which may explain fibronectin expression in the control group of rats [19, 20, 21].

The results of this study were confirmed by Yoshihara et al. [11] examining the distribution of fibronectin in pulp of developing tooth and finalized growth tooth by using indirect immunofluorescence, confocal microscopy. In the apical region of developing tooth, fibronectin was found within the basal membrane and in the first formed predentin layer. A similar representation of fibronectin in the teeth with the finished growth was noted in the odontoblastic layer. Positive fibrous structures between odontoblasts correspond to von Korff's fibers and are associated with differentiation of odontoblasts and dentinogenesis. The authors have indicated that fibronectin was present in the odontoblast layer throughout all phases of dentinogenesis, which could explain its reduced expression in dental pulp of rats with experimentally induced diabetes that were intoxicated with lead in the course of 30 days [11].

An experimental study by Đeri [23], conducted on Wistar rats in which the hyperglycemia was experimentally caused by intraperitoneal administration of alloxan, affirmed a slower metabolism of pulp in diabetic rats than in healthy rats and weaker effects of direct covering of the pulp regardless of the material used, mineral trioxide aggregate (MTA) or calcium hydroxide. In her study she also concluded that microangiopathy in the dental pulp is probably one of the reasons for these findings, giving that the blood vessels with the increased lumen were noticed on the large number of sections of the dental pulp of rats [23].

It has been confirmed that matrix molecules, including fibronectin, growth factors and progenitor pulp cells as well as their interaction mainly stimulate dentinogenesis [20, 24].

Functional researches support the hypothesis that TGF- β 1 plays an important role in stimulation of odontoblast metabolism. In *in vitro* conditions it passes through dental papilla and increases the secretion of collagen type I and fibronectin. It is considered not to affect the polarization of peripheral cells of the dental papilla. The synthesized and released growth factors are embedded in the dentin matrix and remain inactive until it dissolves or demineralizes. The

inductive influence of TGF- β 1 has been noted in those studies where heparin was replaced by fibronectin, which also has affinity for TGF- β 1 [9, 25].

Tziafas et al. [25] explained in more details the structure of pathological dentin, which was also noted in the teeth of rats with experimentally induced DM in this study. The aforementioned authors observed cells different from odontoblasts and pointed out that there were specific stimuli – growth factor TGF- β 1 and fibronectin in the pulp tissue surrounding, which initiate and lead this process.

Ignotz and Massague [26] pointed out that the effect of TGF- β 1 on fibronectin expression was rapid, selective, specific and stable. In the research conducted on the fibroblasts of 12 days old chicken embryos, a significant increase in fibronectin has been noted in the extracellular matrix under the influence of TGF- β 1 growth factor.

In experimental research on dogs where biomatrix within the tooth's pulp chamber served as a sample, Tziafas et al. [25] explained the molecular basis of induction of the creation of reparative dentin. Namely, the pulp tissue of the experimental animals was implanted with Millipore filter soaked with fibronectin, which affected the formation of dentin matrix around the implant and the appearance of cells similar to odontoblasts. Wieser et al. [10] in their study came to the same conclusion that the pulp cells covered with fibronectin can be differentiated into cells similar to odontoblasts. In this case, fibronectin binds growth factors, in particular TGF- β 1 and affects the initiation of dentinogenesis. These findings are in accordance with the results of our immunohistochemical examination.

Some studies showed that pulp microcirculation is an important factor in metabolic activity and dentinogenesis [12, 13, 26, 27, 28]. Using pathohistological analysis Madani et al. [15] studied changes in the pulp after direct covering in the Wistar rats which were induced into diabetes. Intense inflammatory response was found in the pulp that was covered with calcium-enriched mixture (CEM) cement compared to the pulp of the teeth treated with MTA.

In various phases of dentinogenesis, Linde et al. [29] examined the expression of fibronectin by using indirect fluorescence. Fibronectin and its expression were established in the basement membrane between the inner enamel epithelium and the primary dental mesenchyme and in the predentin layer, but were not represented in the predentin during further, circum-pulpal formation of dentin. That indicates that the fibronectin molecules were not directly involved in mineralization. Fibronectin was localized in the odontoblast layer.

In vivo animal models used in this study, provide an acceptable alternative to human models, although differences between species should be taken into account while interpreting tissue response [30].

CONCLUSION

Expression of fibronectin was higher in the group of rats with experimentally-induced DM that received lead through drinking water in the course of 14 days compared to the group of rats that received lead in the course of 30 days. Reparative dentinogenesis and fibronectin expression were reduced under the influence of DM, but also insufficiently stimulated in rats that had been intoxicated by lead through drinking water for a shorter period.

ACKNOWLEDGMENT

This paper was part of a research thesis on *Lead Impact on Distribution of Odontogenesis Mediators in Diabetes-Changed Dental Pulp* by Irena Kuzmanović-Radman. The thesis was successfully defended at the Faculty of Medicine of the University of Banja Luka (Banja Luka, Republic of Srpska, Bosnia and Herzegovina) in June 2017.

Conflict of interest: None declared.

REFERENCES

- Olovčić A, Ramić E, Memić M. Human Enamel and Dentin: Effect of Gender, Geographic Location and Smoking Upon Metal Concentrations. *Anal Lett.* 2019;53(3):245–61.
- Ben Said A, Telmoudi C, Louati K, Telmoudi F, Amira D, Hsairi M, et al. Evaluation of the reliability of human teeth matrix used as a biomarker for fluoride environmental pollution. *Ann Pharm Fr.* 2020;78(1):21–33.
- Neves VCM, Sharpe PT. Regulation of Reactionary Dentine Formation. *J Dent Res.* 2018;97(4):416–22.
- Tziafas D. Characterization of Odontoblast-like Cell Phenotype and Reparative Dentin Formation In Vivo: A Comprehensive Literature Review. *J Endod.* 2019;45(3):241–9.
- Vaseenon S, Chattipakorn N, Chattipakorn SC. The possible role of basic fibroblast growth factor in dental pulp. *Arch Oral Biol.* 2020;109:104574.
- Hamed NH, Gharakhanlou R, Peeri M. The Effect of Endurance Training on Fibronectin Gene Expression of the Sciatic Nerve in Diabetic Rats. *Acta Medica Iranica.* 2020;58(2):50–5.
- Thaweboon S, Chunhabundit P, Surarit R, Swadison S, Suppukpatana S. Effects of lead on the proliferation, protein, production, and osteocalcin secretion of human dental pulp cells in vitro. *Southeast Asian J Trop Med Public Health.* 2002;33(3):654–61.
- Sutunkova MP, Solovyeva SN, Chernyshov IN, Klinova SV, Gurvich VB, Shur VY, et al. Manifestation of Systemic Toxicity in Rats after a Short-Time Inhalation of Lead Oxide Nanoparticles. *Int J Mol Sci.* 2020;21(3):690.
- Tziafas D, Papadimitriou S. Role of exogenous TGF- β in induction of reparative dentinogenesis in vivo. *Eur J Oral Sci.* 1998;106 Suppl 1:192–6.
- Wieser R, Attisano L, Wrana JL, Massague J. Signaling activity of transforming growth factor β type II receptors lacking specific domains in the cytoplasmic region. *Mol Cell Biol.* 1993;13(12):7239–47.
- Yoshida K, Yoshida N, Nakamura H, Iwaku M, Ozawal H. Immunolocalization of Fibronectin during Reparative Dentinogenesis in Human Teeth after Pulp Capping with Calcium Hydroxide. *J Dent Res.* 1996;75(8):1590–7.
- Leite MF, Ganzerla E, Marques MM, Nicolau J. Diabetes induces metabolic alterations in dental pulp. *J Endod.* 2008;34(10):1211–4.
- Moraru AI, GheorghiiȚă LM, Dascălu IT, Bătăiosu M, Manolea HO, Agop Forna D, et al. Histological and immunohistochemical study on the dental pulp of patients with diabetes mellitus. *Rom J Morphol Embryol.* 2017;58(2):493–9.

14. Guide laboratory animals for the care and use of laboratory animals. Eighth edition. Washington: The national academies press.; 2011.
15. Madani ZS, Haddadi A, Mesgarani A, Seyedmajidi M, Mostafazadeh A, Bijani A, et al. Histopathologic Responses of the Dental Pulp to Calcium-Enriched Mixture (CEM) and Mineral Trioxide Aggregate (MTA) in Diabetic and Non-Diabetic Rats. *Int J Mol Cell Med.* 2014;3(4):263–71.
16. Mirescu ȘC, Păiș R, Stănoiu BP, Di Natale L, Șovrea AS. The value of exfoliative cytology in the diagnostic of oral mucosa changes in diabetes mellitus. *Rom J Morphol Embryol.* 2016;57(4):1313–22.
17. Tort B, Choi YH, Kim EK, Jung YS, Ha M, Song KB, et al. Lead exposure may affect gingival health in children. *BMC Oral Health.* 2018;18(1):79.
18. Dantas de Souza I, Silveira de Andrade A, Juliani Siqueira Dalmolin R. Lead-interacting proteins and their implication in lead poisoning. *Crit Rev in Toxicol.* 2018;48(5):375–86.
19. Eftimoska M, Rendzova V, Apostolska S, Elencevski S, Ristovska S, Pavlevska M, et al. Expression of Fibronectin and Tenascin after Direct Capping of the Pulp with Mineral Trioxide Aggregate and Biodentine®. *Open Access Maced J Med Sci.* 2020;8:64–9.
20. Tang J, Saito T. Human plasma fibronectin promotes proliferation and differentiation of odontoblast. *J Appl Oral Sci.* 2017;25(3):299–309.
21. Kawashima N, Okiji T. Odontoblasts: Specialized hard-tissue-forming cells in the dentin-pulp complex. *Congenit Anom (Kyoto).* 2016;56(4):144–53.
22. Er F, Koparal M, Devenci E, Irtegin S. Immunohistochemical and histopathological changes in the teeth of rats after lead acetate application. *Anal Quant Cytopathol Histopathol.* 2015;37(2):109–14.
23. Đeri A. Efekti mineral trioksid agregata i kalcijum hidroksida na pulpu zuba pacova sa eksperimentalno izazvanim diabetes mellitus-om tipa 1 [magistarska teza]. Medicinski fakultet Banja Luka; 2014.
24. Wang F, Xie C, Ren N, Bai S, Zhao Y. Human Freeze-dried Dentin Matrix as a Biologically Active Scaffold for Tooth Tissue Engineering. *J Endod.* 2019;45(11):1321–33.
25. Tziapas D, Alvanou A, Papadimitriou S, Gasic J, Komnenou A. Effects of recombinant basic fibroblast growth factor, insulin-like growth factor-II and transforming growth factor-β 1 on dog dental pulp cells in vivo. *Arch Oral Bio.* 1988;43(6):431–4.
26. Ignatz RA, J Massagué J. Transforming growth factor-beta stimulates the expression of fibronectin and collagen and their incorporation into the extracellular matrix. *J Biol Chem.* 1986;261(9):4337–45.
27. Moradi S, Saghravanian N, Moushekhian S, Fatemi S, Forghani M. Immunohistochemical Evaluation of Fibronectin and Tenascin Following Direct Pulp Capping with Mineral Trioxide Aggregate, Platelet-Rich Plasma and Propolis in Dogs' Teeth. *Iran Endod J.* 2015;10(3):188–92.
28. Ghavimishamekh A, Ziamajidi N, Dehghan A, Goodarzi MH, Abbasalipourkabir R. Study of Insulin-Loaded Chitosan Nanoparticle Effects on TGF-β1 and Fibronectin Expression in Kidney Tissue of Type 1 Diabetic Rats. *Ind J Clin Biochem.* 2019;34(4):418–26.
29. Linde A, Goldberg M. Dentinogenesis. *Crit Rev Oral Biol Med.* 1993;4(5):679–728.
30. Fletcher A, Bregman C, Woicke J, Salcedo T, Zidell R, Janke H. Incisor degeneration in rats induced by vascular endothelial growth factor/fibroblast growth factor receptor

Експресија фибронектина у пулпи зуба пацова интоксикованих оловом са екпериментално изазваним дијабетесом мелитусом

Ирена Кузмановић-Радман¹, Александра Ђери¹, Радослав Гајанин², Адриана Арбутина³, Рената Јосиповић¹, Славољуб Живковић⁴

¹Универзитет у Бањој Луци, Медицински факултет, Катедра за болести зуба, Студијски програм – стоматологија, Бања Лука, Република Српска, Босна и Херцеговина;

²Универзитет у Бањој Луци, Медицински факултет, Катедра за патологију, Бања Лука, Република Српска, Босна и Херцеговина;

³Универзитет у Бањој Луци, Медицински факултет, Катедра за ортопедију вилица, Студијски програм – стоматологија, Бања Лука, Република Српска, Босна и Херцеговина;

⁴Универзитет у Београду, Стоматолошки факултет, Катедра за болести зуба, Београд, Србија

САЖЕТАК

Увод/Циљ Изложеност организма олову представља један од значајнијих фактора који утичу на опште здравље укључујући орално здравље, те има утицај на настанак глеђних и дентинских дефеката.

Циљ овог рада је био да се имунохистохемијском анализом одреди експресија медијатора одонтогенезе фибронектина у пулпи зуба пацова са екпериментално изазваним дијабетесом мелитусом, после излагања животиња олову.

Метод Истраживање је спроведено на 42 пацова соја вистар. Интоксикација адултних пацова оловним ацетатом је урађена путем воде за пиће *ad libitum*. Прву екперименталну групу (*Exp_14*) чинило је 16 пацова који су добијали олово у води 14 дана, другу групу (*Exp_30*) 16 пацова који су добијали олово у води 30 дана у истој концентрацији (1500 ppm), док је контролну групу чинило 10 здравих пацова. Групе пацова *Exp_14* и *Exp_30* су уведене у дијабетес ме-

литус помоћу раствора алоксана, који је апликован интраперитонеално. Патохистолошком и имунохистохемијском анализом одређивана је експресија фибронектина у пулпи, одонтобластима, предентину и дентину зуба екперименталних животиња.

Резултати Висока дифузна позитивност фибронектина у групи *Exp_14* је уочена у 63,6% случајева, у групи *Exp_30* у 24% случајева, док је у контролној групи уочена у 50% случајева. Није уочена статистички значајна разлика у експресији фибронектина између испитиваних група.

Закључак Интоксикација оловом путем воде за пиће, у периоду од 14 и 30 дана, имала је утицај на експресију фибронектина у пулпи, одонтобластима, предентину и дентину зуба животиња са екпериментално изазваним дијабетесом мелитусом.

Кључне речи: фибронектин; одонтогенеза; дијабетес; олово