

# Photogrammetric analysis of postextraction space closure

Mirjana Umićević Davidović<sup>1</sup>, Marijana Arapović Savić<sup>1</sup>, Adriana Arbutina<sup>1</sup>, Tijana Adamović<sup>2</sup>, Igor Đukić<sup>3</sup>

<sup>1</sup>University of Banja Luka, Faculty of Medicine, Department of Orthodontics, Banja Luka, Republic of Srpska, Bosnia and Herzegovina;

<sup>2</sup>University of Banja Luka, Faculty of Medicine, Department of Periodontology and Oral Medicine, Banja Luka, Republic of Srpska, Bosnia and Herzegovina;

<sup>3</sup>University of Banja Luka, Faculty of Medicine, Department of Oral Surgery, Banja Luka, Republic of Srpska, Bosnia and Herzegovina

## SUMMARY

**Introduction** When planning orthodontic treatment, it is sometimes necessary to apply the extraction of individual teeth, in order to achieve proper occlusion and an acceptable aesthetic appearance. Clinicians give the greatest advantage to elastic chains as a method for post-extraction space closure during treatment with fixed orthodontic appliances. When closing post-extraction spaces, it is necessary to measure them in order to adjust the treatment plan. One of the most acceptable methods is photogrammetry.

The aim of this study was to analyze, using a photogrammetric method, the efficacy of post-extraction space closure with elastic chains during orthodontic treatment with fixed orthodontic appliances.

**Material and Methods** The total sample in study consisted of 38 post-extraction spaces in 19 patients who were indicated for first premolars extraction and use of fixed orthodontic appliances in order to achieve treatment goal. Elastic chains were used to close post-extraction spaces. Post-extraction sites were monitored for 6 months with follow-up examinations every 4 weeks. Mechanisms were activated at controlled examinations, and measurements of the width of post-extraction spaces were performed by photogrammetry and digital caliper.

**Results** The results showed that average reduction of post-extraction space width was 1.00 mm per month by photogrammetric measurement, while the average values of measurements with a digital caliper were 1.02 mm. The average values were measured in six time intervals and a statistically significant change in average intervals of post-extraction spaces during 6 months was determined.

**Conclusion** The elastic chain has proven to be a very effective mechanism for closing post-extraction space, and photogrammetry as a simple and precise method for monitoring results of treatment. Since the difference in relation to measurements with a digital caliper is minimal, photogrammetry can be routinely applied in everyday practice.

**Keywords:** photogrammetry; elastic chain; post-extraction space

## INTRODUCTION

When planning orthodontic treatment, it is sometimes necessary to apply extraction of individual teeth, in order to achieve proper occlusion and an acceptable aesthetic appearance. The first premolar is usually the tooth of choice in extraction treatment with fixed orthodontic appliances. Closing the post-extraction space is performed by different methods, and two basic ones are sliding mechanism and methods without friction using loops [1]. The use of a sliding mechanism for post-extraction space closure is very common in clinical practice due to its simplicity. Studies show that clinicians give the greatest advantage to elastic chains as a method for this type of treatment [2, 3].

Although they were introduced in practice in the 1960s, elastic chains remained a traditional method for tooth retraction and space closure in general. Even today, they are one of the most commonly used techniques for closing

space, due to easy application, patient and therapist comfort [4, 5]. They are primarily composed of polyesters or polyethers formed by the polymerization of rubbers with multiple molecular structures linked by a series of urethane bonds [6]. The advantage of elastic chains is that they are not expensive, easy to use and can be applied to various clinical cases. However, they must be changed every 4 to 6 weeks due to plaque retention, difficult hygiene and expected decrease in strength [7]. Therefore, it is necessary to monitor the closure of post-extraction space at control examinations in order to summarize achieved results and correctly direct treatment plan.

By introducing dental photography as an integral part of dental treatment documentation, it is possible to show condition at the beginning and the end, the process and its phases. This way, photographs can be used for various purposes, such as communication with patient, case presentation, diagnosis and treatment plan [8]. Along with

development of digital photography, there was an innovation in the field of dentistry called photogrammetry. This method is using geometric properties of objects that can be determined from photographs and this proved its usefulness in orthodontics for studying three-dimensional occlusion of dental arches, teeth and their dimensions. Chadwick defines photogrammetry as the art, science, and technology of obtaining reliable information about physical objects through the processes of capturing, measuring, and interpreting photographic images [9].

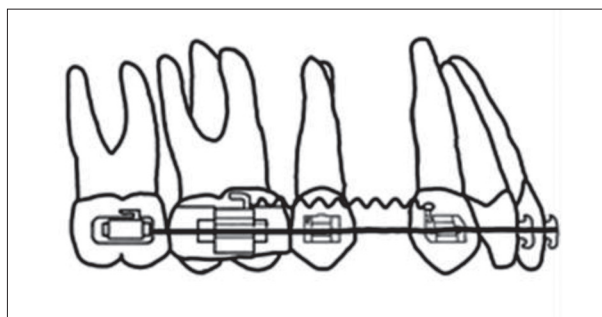
Due to its simplicity, economy and without the danger of radiation, photogrammetry on standardized extra oral and intraoral photographs is used in everyday orthodontic practice [10, 11, 12].

The aim of this study was to analyze using a photogrammetric method the efficacy of post-extraction space closure with elastic chains during orthodontic treatment with fixed orthodontic appliances.

## MATERIAL AND METHODS

The research was conducted at the Faculty of Medicine - study program of Dentistry in Banja Luka, with the consent of the Ethics Committee of the Department of Dentistry. The total sample consisted of 38 post-extraction spaces in 19 patients who were indicated for the extraction of the first premolars in order to conduct orthodontic treatment. The age of patients at the beginning of treatment was 12-20 years, who did not have contraindications for orthodontic treatment and who had no other extractions (except for the first premolars). Subjects who had poor oral hygiene, who came for check-ups irregularly and did not follow the instructions given at the beginning of treatment, were excluded from the study.

After extraction of first premolars, fixed orthodontic appliance was applied to the subjects (Dentaurum, Discovery,

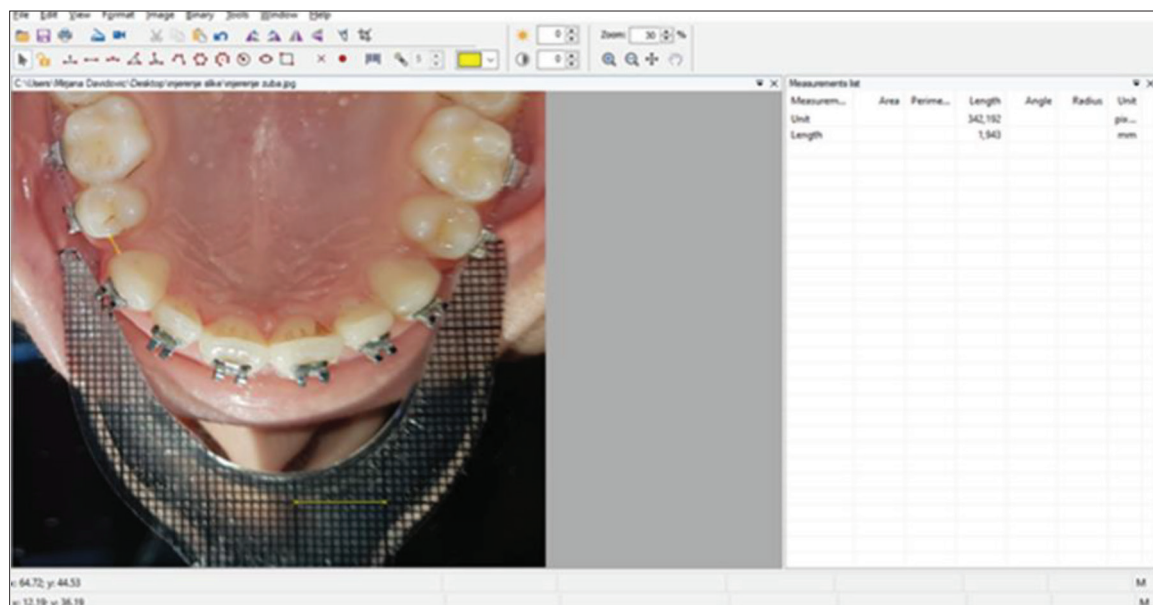


**Figure 1.** Method for placement of the elastic chain  
**Slika 1.** Metoda postavljanja elastičnog lanca

Roth prescription, slot 0.022 in), and then, initial leveling with round and rectangular NiTi arches was performed, before the placement of steel rectangular arches. A rectangular steel arch wire of 0.019×0.025 in was left in brackets slots for at least 4 weeks, to become passive, and then elastic chains were applied. The elastic chain was placed to connect the hook on the tube of the first molar and the hook of the bracket on the canine, whereby it is stretched to approximately twice the initial length, and on control examinations it was replaced with a new one (Figure 1).

Post-extraction spaces were monitored for 6 months from the beginning of the application of elastic chains at intervals of one month ( $T_0$ - $T_6$ ). Control examinations were performed every 4 weeks and it was checked whether there was damage to applied mechanisms and their activation.

For the photogrammetric method, a Canon camera (EOS 750D Body) with macro lens (EF 100 mm / 2.8 IS USM) and a ring-shaped flash (macro Ring Lite MR-14 EXII), a flat occlusal mirror and a retractor for occlusal photography with millimeter scale were used. During regular check-ups ( $T_0$ - $T_6$ ), standardized occlusal photographs of the upper and lower dental arch were obtained. When photographing, the mirror rested on the opposite dental



**Figure 2.** Photogrammetry measurement of postextraction space  
**Slika 2.** Merenje postekstrakcionog prostora fotogrametrijom

arch, while the retractor was placed parallel to the dental arch being photographed.

The millimeter scale on the retractor enabled the measurement results to be recognized by software with the computer program Digimizer for photo analysis and processing. Using this program, linear measurements in pixels were obtained. Then, the number of pixels in one centimeter that was on the retractor with a millimeter scale was read. This way, one centimeter of a segment of a photograph, measured in pixels, was used as a parameter to convert the number of pixels in a real photograph into centimeters. All measurements in pixels were converted to millimeters through a computer program. The shortest distance from the distal surface of the canine to the mesial surface of the second premolar was measured. Measurements were performed 3 times alternately, and the reference value represented the mean value of these 3 measurements (Figure 2).

In order to establish the accuracy of this method, measurements were also performed using a digital caliper with an accuracy of 0.01 mm. The direct distance from the distal surface of the canine to the mesial surface of the second premolar was measured by direct method. These measurements were performed for each post-extraction space 3 times alternately. The reference value was the mean of these 3 measurements.

## RESULTS

For measuring the efficiency of the elastic chain, the photogrammetry method was used. The Tukey test was used to test whether there was a difference between all time intervals measuring the space between teeth by this method. This test showed that a statistically significant difference exists between all time intervals. The average distance between the teeth decreased over time, and the average distance of post-extraction space at the beginning of the measurement ( $T_1$ ) was  $4.03 \pm 1.44$  mm, while at the final measurement ( $T_6$ ) it was  $0.44 \pm 0.57$  mm (Table 1).

Using one-factor analysis of Repeated Measure ANOVA, it was examined whether there was a statistically significant change in the average values of post-extraction spaces when using the elastic chain method measured by photogrammetry. Mean values were measured at six time intervals and a statistically significant change in the average intervals of post-extraction spaces over 6 months was found (Wilks' lambda = 0.019,  $F = 103.98$ ,  $p = 0.000$ ). The influence of the elastic chain as a mechanism of post-extraction spaces closure was also examined. The value of the Wilks lambda of 0.01-small influence, 0.06-moderate influence and 0.14-big influence, and the obtained  $\eta^2$  of 0.98, indicates a very large influence of the elastic chain as a mechanism of post-extraction space closure (Table 2). The graph shows the reduction of the average values of post-extraction spaces measured by the method of photogrammetry, under the action of an elastic chain (Figure 3). Control measurements were performed by a direct method using digital caliper. The average distance of the post-extraction space at the beginning of the measurement ( $T_1$ )

**Table 1.** Average values of maximum distance (mm) between teeth measured by photogrammetry

**Tabela 1.** Prosečne vrednosti maksimalnog rastojanja (mm) među zubima merenog fotogrametrijom

	N	Min	Max	M	SD	Percentage of reduction Procenat smanjenja
$T_1$ photogrammetry $T_1$ fotogrametrija	38	1.85	6.67	4.03	1.44	
$T_2$ photogrammetry $T_2$ fotogrametrija	38	0.88	5.75	2.94	1.47	-27.04
$T_3$ photogrammetry $T_3$ fotogrametrija	38	0	4.93	1.91	1.47	-52.60
$T_4$ photogrammetry $T_4$ fotogrametrija	35	0	3.83	1.23	1.32	-69.47
$T_5$ photogrammetry $T_5$ fotogrametrija	24	0	2.49	0.87	0.87	-78.41
$T_6$ photogrammetry $T_6$ fotogrametrija	15	0	1.46	0.44	0.57	-89.08

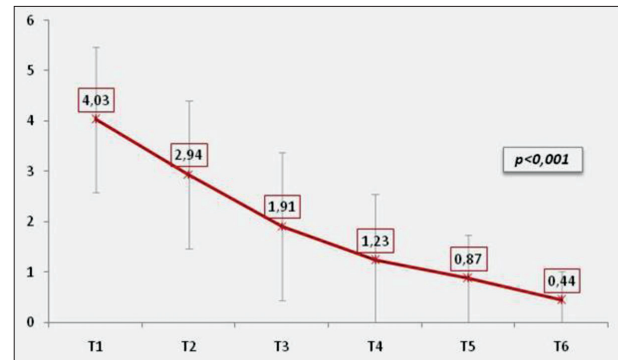
N – number of subjects; Min – minimum value on the sample; Max – maximum value on the sample; M – arithmetic mean; SD – standard deviation;  
N – broj ispitanika; Min. – minimalna vrednost na uzorku; Max. – maksimalna vrednost na uzorku; M – aritmetička sredina; SD – standardna devijacija

**Table 2.** Differences in values of maximum distance (mm) between teeth measured by a photogrammetry in six time intervals

**Tabela 2.** Razlike u vrednostima maksimalnog rastojanja (mm) među zubima merenog fotogrametrijom u šest vremenskih intervala

Wilks' Lambda	F	P	$\eta^2$
0.019	103.98	0.000	0.981

F – ANOVA of repeated measurements; p – statistical significance;  $\eta^2$  – squared Eta;  
F – ANOVA ponovljenih merenja; p – statistička značajnost;  $\eta^2$  – kvadrirana Eta



**Slika 3.** Graphic representation of average values for maximum distance (mm) between teeth measured by photogrammetry

**Slika 3.** Grafički prikaz prosečnih vrednosti maksimalnog rastojanja (mm) među zubima merenog fotogrametrijom

was  $4.14 \pm 1.47$  mm, and at the end ( $T_6$ )  $0.46 \pm 0.59$  mm (Table 3).

A statistically significant difference was found in the average intervals of post-extraction spaces during 6 months (Wilks' lambda = 0.006,  $F = 322.06$ ,  $p = 0.000$ ). The influence of the elastic chain, as a mechanism of space closure between the teeth, was also examined. In this case, the obtained  $\eta^2$  is 0.99, which indicates a very large influence of the elastic chain as a mechanism of reducing space between the teeth (Table 4). Figure 4 graphically shows the average values of post-extraction space width, that is, the maximum distance between the teeth when using an elastic chain measured with a digital caliper.

**Table 3.** Average values of maximum distance (mm) between teeth measured by a digital caliper**Tabela 3.** Prosečne vrednosti maksimalnog rastojanja (mm) među zubima merenog digitalnim kaliperom

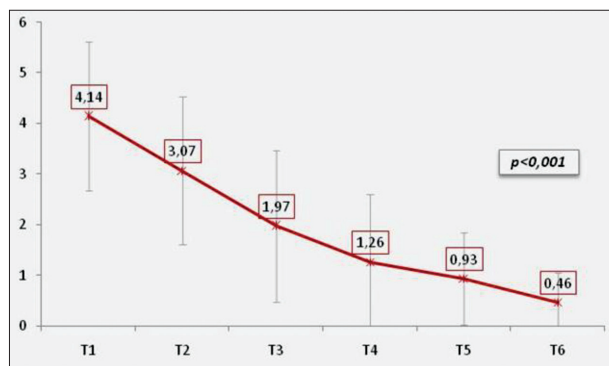
	N	Min	Max	M	SD	Percentage of reduction Procenat smanjenja
T <sub>1</sub> digital caliper T <sub>1</sub> digitalni kaliper	38	1.84	6.83	4.14	1.47	/
T <sub>2</sub> digital caliper T <sub>2</sub> digitalni kaliper	38	1.01	5.77	3.07	1.47	-25.84
T <sub>3</sub> digital caliper T <sub>3</sub> digitalni kaliper	38	0	4.99	1.97	1.49	-52.41
T <sub>4</sub> digital caliper T <sub>4</sub> digitalni kaliper	35	0	3.87	1.26	1.34	-69.56
T <sub>5</sub> digital caliper T <sub>5</sub> digitalni kaliper	24	0	2.66	0.93	0.91	-77.53
T <sub>6</sub> digital caliper T <sub>6</sub> digitalni kaliper	15	0	1.58	0.46	0.59	-88.88

N – number of subjects; Min – minimum value on the sample; Max – maximum value on the sample; M – arithmetic mean; SD standard deviation;  
N – broj ispitanika; Min. – minimalna vrednost na uzorku; Max. – maksimalna vrednost na uzorku; M – aritmetička sredina; SD – standardna devijacija

**Table 4.** Differences in values of maximum distance (mm) between teeth measured with a digital caliper in six time intervals**Tabela 4.** Razlike u vrednostima maksimalnog rastojanja (mm) među zubima merenog digitalnim kaliperom u šest vremenskih intervala

Wilks' Lambda	F	P	$\eta^2$
0.006	322.06	0.000	0.994

F – ANOVA of repeated measurements; p – statistical significance;  $\eta^2$  – squared Eta;  
F – ANOVA ponovljenih merenja; p – statistička značajnost;  $\eta^2$  – kvadrirana Eta

**Figure 4.** Graphic representation of average values of maximum distance (mm) between teeth measured with a digital caliper**Slika 4.** Grafički prikaz prosečnih vrednosti maksimalnog rastojanja (mm) među zubima merenog digitalnim kaliperom

## DISCUSSION

It has been shown that among clinicians, sliding mechanics is the most commonly used method for the post-extraction space closure [13]. The possibility of quick and easy reactivation with minimal bending of the wire and saving time are the advantages that make sliding mechanism the method of choice during treatment of extraction spaces closure [14]. The results of research conducted in Brazil by Monnini et al. confirmed that most specialists (63.81%) prefer a technique based on sliding mechanics, while elastic chains are among the most used methods [2].

In a similar study in Great Britain, they came to the conclusion that loops are practically not used for space closure, and the sliding technique was used in 98% of cases [3].

Chitra and Prakash analyzed the use of photogrammetry in orthodontic diagnosis and treatment planning. They found that occlusal photogrammetric analysis could be used as an adjunct to the analysis of study models and to assess treatment progress. In cases where appliances for expansion were used, photogrammetric measurement of intercanine distance, anterior and posterior widths could be used periodically for quantitative monitoring to determine the change during treatment [12]. They can also be used to measure the mesiodistal dimension of the tooth and to calculate the Bolton mismatch, as well as to plan the correction of deviations from the midline [13].

The results of this study showed that post-extraction spaces were closed by an average of 1.00 mm per month when measurements were performed by photogrammetry. Control measurements with a digital caliper gave average values of 1.02 mm per month. Both methods confirmed the high efficiency of elastic chains in post-extraction space closure.

Numerous authors have analyzed post-extraction space closure in different ways [14, 15]. Direct measurement with a digital caliper has proven to be the simplest method for both the patient and the therapist. The biggest advantage is that the measurement results are obtained immediately, which can be of great importance for assessing the success so far and treatment planning. This method was used by Dixon et al., who used elastic chains in 10 patients and found that the space was closed by 0.58 mm per month [4]. A similar study was conducted by Chaudhari and Tarvade observing the closure of postextraction spaces in 20 patients. During 4 months, measurements were performed using a digital caliper from the tip of the canine to the tip of the mesiobuccal cusp on the first permanent molar, and they found that this value decreased by 0.62 mm per month [16]. Direct measurement was used by both Kanuru et al. when examining the amount of space closure by moving the canines using 4 different elastic chains over 6 weeks. They measured the distance from the hook of the bracket on the canine to the hook of the tube on the first molar. After 3 weeks, the measured values for space closure ranged from 0.75 mm to 1.12 mm, while after 6 weeks these values ranged from 1.47 mm to 2.07 mm [17]. However, the biggest disadvantage of this method is the correct positioning of the caliper arms, because the measurement is performed in a limited space in a humid environment, so it can happen that wrong results occur.

Indirect measurements involve taking impressions at check-ups, which allows the orthodontist greater comfort for analysis and measurement. This method was used by Talwar and Bath who also examined the efficiency of elastic chains. Impressions were taken at the beginning and at the end of the observed 12-week period. Measurements were performed on study models from the tip of the canine to the tip of the mesiobuccal cusp on the first permanent molar. The average values were  $1.62 \pm 0.14$  mm per month [18]. Fang et al. conducted a similar study, but the measurement points were located at the tip of the canine and

in the middle of the central fissure of the second premolar, while the space was closed by 0.52 mm per month [19].

Sabrina et al. investigated the closure of post-extraction spaces in self-ligating and conventional locks using an elastic chain in 11 patients over 8 weeks. At the control examinations, the arches were removed, and the prints were taken through brackets that were protected with wax. Measurements were performed indirectly on the obtained study models, from the distal surface of the canine to the mesial surface of the second premolar using a digital caliper. The average value for conventional brackets was 0.75 mm, and for self-ligating 0.48 mm per month [20].

A similar split-mouth study was conducted by Mezomo et al. comparing conventional and self-ligating brackets, and as a sliding mechanism an elastic chain. Impressions were taken at the monthly controls, and measurements were performed by the indirect method with digital caliper. The results showed that the space closure with conventional brackets takes place at a rate of 0.84 mm per month; while for self-ligating locks this value was 0.90 mm per month [21]. The biggest disadvantage of indirect measurement is that the time of the control inspection is extended, and the inadvertent detachment of the brackets can contribute to that even more, which requires additional time planning.

Bokas and Woods observed the closure of 12 post-extraction spaces by sliding mechanics using elastic chains. Control examinations were performed at 28-day intervals and impressions were taken for study models which were then scanned. Measurements were performed on digital photographs obtained by occlusal scanning using the appropriate software. The results showed that elastic chains closed spaces by 1.68 mm per month [22]. Scanning models and analyzing their 3D replicas gives the orthodontist the ability to measure in three dimensions, and software manipulation allows monitoring and prediction of treatment results. However, properly analyzing and measuring scanned models requires practice and a good knowledge of the capabilities provided by the software.

Like previous methods, photogrammetry has its advantages and disadvantages. The advantage is first of all that you avoid taking impressions. The record obtained by this method is in color and faithfully depicts the area of measurement, but also the structures around it. Another advantage of digital photos is that the image can be repeated immediately if it is not satisfactory, and the measurements can be done later without haste. In addition to a certain inconvenience when taking photos, the biggest drawback of this method is the lack of a third dimension. Therefore, it is necessary that the picture taking conditions be standardized.

## CONCLUSION

The elastic chain has proven to be a very effective mechanism for closing the post-extraction space, and photogrammetry is a simple and precise method for monitoring treatment results. Since the difference in relation to measurements with a digital caliper is minimal,

photogrammetry can be routinely applied in everyday practice.

## REFERENCES

- Ribeiro GL, Jacob HB. Understanding the basis of space closure in orthodontics for a more efficient orthodontic treatment. *Dent Press J Orthod*. 2016;21(2):115–25. [DOI: 10.1590/2177-6709.21.2.115-125.sar] [PMID: 27275623]
- Monini AC, Gandini LG, Jr, Santos-Pinto A, Maia LG, Rodrigues WC. Procedures adopted by orthodontists for space closure and Anchorage control. *Dental Press J Orthod*. 2013;18(6):86–92. [DOI: 10.1590/S2176-94512013000600013]
- Banks P, Elton V, Jones Y, Rice P, Derwent S, Odondi L. The use of fixed appliances in the UK: a survey of specialist orthodontists. *J Orthod*. 2010;37(1):43–55. [DOI: 10.1179/14653121042867] [PMID: 20439926]
- Dixon V, Read MJ, O'Brien KD, Worthington HV, Mandall NA. A randomized clinical trial to compare three methods of orthodontic space closure. *J Orthod*. 2002;29(1):31–6. [DOI: 10.1093/ortho/29.1.31] [PMID: 11907307]
- Samuels RH, Rudge SJ, Mair LH. A comparison of the rate of space closure using a nickel-titanium spring and an elastic module: a clinical study. *Am J Orthod Dentofacial Orthop*. 1993;103(5):464–7. [DOI: 10.1016/S0889-5406(05)81798-6] [PMID: 8480716]
- Cheng HC, Chen MS, Peng BY, Lin WT, Shen YK, Wang YH. Surface Treatment on Physical Properties and Biocompatibility of Orthodontic Power Chains. *Biomed Res Int*. 2017;2017:ID6343724.
- Buchmann N, Senn C, Ball J, Brauchli L. Influence of initial strain on the force decay of currently available elastic chains over time. *Angle Orthod*. 2012;82(3):529–35. [DOI: 10.2319/062011-399.1] [PMID: 22077188]
- Mladenovic D, Mladenovic L, Mladenovic S. Importance of digital dental photography in the practice of dentistry. *Sci J Faculty Med in Niš* 2010;27(2):75–9.
- Chadwick RG. Close range photo grammetry-A clinical dental research tool. *J Dent* 1992;20(4):235–9. [DOI: 10.1016/0300-5712(92)90093-r] [PMID: 1430514]
- Andrade LM. Repeatability study of angular and linear measurements on facial morphology analysis by means of stereophotogrammetry. *J Craniofac Surg*. 2017;28(4):1107–11. [DOI: 10.1097/SCS.00000000000003554] [PMID: 28212123]
- Pandian KS, Krishnan S, Kumar SA. Angular photogrammetric analysis of the soft-tissue facial profile of Indian adults. *Indian J Dent Res*. 2018;29(2):137–43. [DOI: 10.4103/ijdr.IJDR\_496\_16] [PMID: 29652003]
- Chitra P, Prakash A. Photogrammetry as a tool to aid orthodontic diagnosis and treatment assessment. *J Contemp Orthod*. 2017;1(2):46–51.
- Arapović-Savić M, Savić M, Umićević-Davidović M, Arbutina A, Nedeljković N, Glišić B. Primena fotogrametrije za prostorne analize u ortodontskoj dijagnostici. *Stomatološki glasnik Srbije*. 2018;65(2):78–88. [DOI: 10.2478/sdj-2018-0008]
- Kulshrestha RS, Tandon R, Chandra P. Canine retraction: A systematic review of different methods used. *Orthod Sci*. 2015;4(1):1–8. [DOI: 10.4103/2278-0203.149608] [PMID: 25657985]
- Umićević-Davidović M, Arapović-Savić M, Arbutina A. Ispitivanje brzine zatvaranja postekstrakcionog prostora elastičnim lancem i niti zatvorenim spiralnim oprugama. *Stomatološki glasnik Srbije*. 2018;65(4):179–86. [DOI: 10.2478/sdj-2018-0017]
- Chaudhari CV, Tarvade SM. Comparison of rate of retraction and anchorage loss using nickel titanium closed coil springs and elastomeric chain during the en-masse retraction: A clinical study. *J Orthod Res*. 2015;3:129–33. [DOI: 10.4103/2321-3825.150582]
- Kanuru RK, Azaneen M, Narayana V, Kolasani B, Indukuri RR, Babu PF. Comparison of canine retraction by in vivo method using four brands of elastomeric power chain. *J Int Soc Prev Community Dent*. 2014;4(1):32–7. [DOI: 10.4103/2231-0762.144586] [PMID: 25452925]

18. Talwar A, Bhat, S.R. Comparative evaluation of Nickel-Titanium closed coil spring and Elastomeric chain for canine retraction. A Randomized Clinical Trial. *IOSR J Dent Med Sci.* 2018;17(10):70–5. [DOI: 10.9790/0853-1710097075]
19. Fang S, Zhong Y, Li M, Luo J, Khadka N, Jiang C, et al. Comparing two methods of orthodontics space closure: a randomized clinical trial. *Int J Clin Exp Med.* 2017;10(10):14667–72.
20. Sabrina, Krisnawati, Soegiharto BM. The comparison of space closure rate between conventional and passive self-ligating system using elastomeric chain in maxilla. *J Int Dent Med Res.* 2016;9:356–61.
21. Mezomo M, de Lima ES, de Menezes LM, Weissheimer A, Allgayer S. Maxillary canine retraction with self-ligating and conventional brackets. *Angle Orthod.* 2011;81(2):292–7. [DOI: 10.2319/062510-348.1] [PMID: 21208082]
22. Bokas J, Woods M. A clinical comparison between nickel titanium springs and elastomeric chains. *Aust Orthod J.* 2006;22(1):39–46. [PMID: 16792244]

---

Received: 18.01.2021 • Accepted: 113.04.2021

# Fotogrametrijska analiza zatvaranja postekstrakcionog prostora

Mirjana Umićević Davidović<sup>1</sup>, Marijana Arapović Savić<sup>1</sup>, Adriana Arbutina<sup>1</sup>, Tijana Adamović<sup>2</sup>, Igor Đukić<sup>3</sup>

<sup>1</sup>Univerzitet u Banjoj Luci, Medicinski fakultet, Katedra za ortopediju vilica, Banja Luka, Republika Srpska, Bosna i Hercegovina;

<sup>2</sup>Univerzitet u Banjoj Luci, Medicinski fakultet, Katedra za parodontologiju i oralnu medicinu, Banja Luka, Republika Srpska, Bosna i Hercegovina;

<sup>3</sup>Univerzitet u Banjoj Luci, Medicinski fakultet, Katedra za oralnu hirurgiju, Banja Luka, Republika Srpska, Bosna i Hercegovina

## KRATAK SADRŽAJ

**Uvod** Prilikom planiranja ortodontske terapije ponekad je potrebno primeniti ekstrakciju pojedinih zuba kako bi se postigla pravilna okluzija i prihvatljiv estetski izgled. Kliničari najveću prednost daju elastičnim lancima kao metodi za zatvaranje postekstrakcionih prostora u toku terapije fiksnim ortodontskim aparatima. Kod zatvaranja postekstrakcionih prostora neophodno je njihovo merenje kako bi se prilagodio plan terapije. Jedna od najprihvatljivijih metoda je fotogrametrija.

Cilj ovog rada je bio da se fotogrametrijskom metodom analizira efikasnost zatvaranja postekstrakcionog prostora sa elastičnim lancima u okviru terapije fiksnim ortodontskim aparatima.

**Materijal i metode** Ukupan uzorak u istraživanju činilo je 38 postekstrakcionih prostora kod 19 pacijenta kojima je indicirana ekstrakcija prvih premolara i primena fiksnog ortodontskog aparata u cilju provođenja terapije. Za zatvaranje postekstrakcionih prostora primenjeni su elastični lanci. Postekstrakcioni prostori su praćeni tokom šest meseci sa kontrolnim pregledima svake četiri sedmice. Na kontrolnim pregledima su aktivirani mehanizmi, a merenja širine postekstrakcionih prostora su obavljena fotogrametrijom i digitalnim nonijusom.

**Rezultati** Rezultati istraživanja pokazuju da je prosečno smanjenje širine postekstrakcionog prostora iznosilo 1,00 mm mesečno merenjem fotogrametrijskom metodom, dok je prosečna vrednosti kontrolnih merenja digitalnim kaliperom iznosila 1,02 mm. Prosečne vrednosti merene su u šest vremenskih intervala i utvrđena je statistički značajna promena u prosečnim razmacima postekstrakcionih prostora tokom šest meseci.

**Zaključak** Elastični lanac se pokazao kao veoma efikasan mehanizam za zatvaranje postekstrakcionog prostora, a fotogrametrija kao jednostavna i precizna metoda za praćenje rezultata terapije. S obzirom da je razlika u odnosu na merenja digitalnim kaliperom minimalna, fotogrametrija se može rutinski primenjivati u svakodnevnoj praksi.

**Ključne reči:** fotogrametrija; elastični lanac; postekstrakcioni prostor

## UVOD

Prilikom planiranja ortodontske terapije, ponekad je potrebno primeniti ekstrakciju pojedinih zuba kako bi se postigla pravilna okluzija i prihvatljiv estetski izgled. Zub izbora u ekstrakcionoj terapiji fiksnim ortodontskim aparatima najčešće je prvi premolar. Zatvaranje postekstrakcionog prostora se provodi različitim metodama, a dve osnovne su klizni mehanizmi i metode bez trenja pomoću omći [1]. Primena kliznog mehanizma za zatvaranje postekstrakcionog prostora je veoma česta u kliničkoj praksi zbog svoje jednostavnosti. Istraživanja pokazuju da kliničari najveću prednost daju elastičnim lancima kao metodi za ovu vrstu terapije [2, 3].

Iako su u praksu uvedeni šezdesetih godina prošlog veka, elastični lanci su ostali tradicionalna metoda za retrakciju zuba i uopšte za zatvaranje prostora. I danas su jedna od najčešće primenjivanih tehnika za zatvaranje prostora zahvaljujući lakoj aplikaciji, komforosti pacijenta i terapeuta [4, 5]. Prvenstveno su sastavljeni od poliestera ili polietera nastalih polimerizacijom guma s višestrukim molekularnim strukturama povezanim nizom uretanskih veza [6]. Prednost elastičnih lanaca je ta što nisu skupi, lako se koriste i mogu se primeniti na različite kliničke slučajeve. Međutim, moraju se menjati svakih 4 do 6 sedmica zbog zadržavanja plaka, otežanog održavanja higijene i očekivanog opadanja sile [7]. Zbog toga je neophodno na kontrolnim pregledima pratiti zatvaranje postekstrakcionog prostora kako bi se sumirali postignuti rezultati i pravilno usmerio plan terapije.

Uvođenjem dentalne fotografije kao sastavnog dela dokumentacije stomatološke terapije, stvorena je mogućnost da se prikaže stanje na početku i na kraju, proces i njene faze. Na

ovaj način fotografije se mogu koristiti u razne svrhe, kao što je komunikacija sa pacijentom, prezentacija slučaja, dijagnostika i plan terapije [8]. Uz razvoj digitalne fotografije, pojavila se i inovacija u oblasti stomatologije koja se naziva fotogrametrija, kroz koju se geometrijska svojstva predmeta mogu odrediti iz fotografija i koja je dokazala svoju korisnost u ortodontskoj praksi [9].

Zbog jednostavnosti, ekonomičnosti i bez opasnosti od zračenja, fotogrametrija se na standardizovanim ekstraoralnim i intraoralnim fotografijama koristi u svakodnevnoj ortodontskoj praksi [10, 11, 12].

Cilj ovog rada je bio da se fotogrametrijskom metodom analizira efikasnost zatvaranja postekstrakcionog prostora sa elastičnim lancima u okviru terapije fiksnim ortodontskim aparatima.

## MATERIJAL I METODE

Istraživanje je sprovedeno na Medicinskom fakultetu – studijski program stomatologija, u Banjaluci, uz saglasnost Etičkog komiteta Zavoda za stomatologiju. Ukupan uzorak u istraživanju činilo je 38 postekstrakcionih prostora kod 19 pacijenta kojima je indicirana ekstrakcija prvih premolara u cilju provođenja ortodontske terapije. Uzrast ispitanika na početku terapije, kod kojih nisu postojale kontraindikacije za ortodontsku terapiju i koji nisu imali druge ekstrakcije (osim prvih premolara), iznosio je

od 12 do 20 godina. Iz istraživanja su isključeni ispitanici koji su imali lošu oralnu higijenu, koji neredovno dolaze na kontrole i ne pridržavaju se datih uputstava na početku terapije.

Posle ekstrakcije prvih premolara ispitanicima je postavljen fiksni ortodontski aparat (*Dentaurum, Discovery, Roth preskripcija, slot 0,022 in*), nakon čega je izvršena početna nivelacija sa NiTi lukovima okruglog i četvrtastog preseka, pre postavljanja čeličnih četvrtastih lukova. Četvrtasti čelični luk preseka  $0,019 \times 0,025$  in je stajao u slotovima bravica najmanje četiri sedmice, da bi postao pasivan, nakon čega su aplicirani elastični lanci. Elastični lanac je postavljan tako da povezuje kukicu na tubi prvog molara i kukicu bravice na očajaku, pri čemu je rastegnuto na približno dvostruku početnu dužinu, a na kontrolnim pregledima je zamenjen novim (Slika 1).

Postekstrakcioni prostori su praćeni šest meseci od početka primene elastičnih lanaca u intervalima od mesec dana ( $T_0 - T_6$ ). Kontrolni pregledi su obavljani svake četiri sedmice i na njima je proveravano da li je došlo do oštećenja apliciranih mehanizama i izvršena njihova aktivacija.

Za fotogrametrijsku metodu korišćen je fotoaparat Canon (EOS 750D Body), makroobjektiv (EF 100 mm/2,8 IS USM) i blic u obliku prstena (macro Ring Lite MR-14 EXII), ravno okluzalno ogledalo i retraktor za okluzalno fotografisanje sa milimetarskom skalom. Fotografisanjem na kontrolnim pregledima ( $T_0 - T_6$ ) dobijene su standardizovane okluzalne fotografije za gornji i donji zubni luk. Prilikom fotografisanja ogledalo se oslanjalo na suprotni zubni luk, dok je retraktor bio postavljen paralelno sa zubnim nizom koji se fotografiraše.

Milimetarska skala na retraktoru je omogućila da se rezultati merenja softverski očitaju kompjuterskim programom Digimizer za analizu i obradu fotografije. Pomoću ovog programa dobijeno je linearno merenje u pikselima. Zatim je očitani broj piksela u jednom centimetru koji se nalazio na retraktoru sa milimetarskom skalom. Na ovaj način jedan centimetar segmenta fotografije, meren u pikselima, koristio se kao parametar da se broj piksela na realnoj fotografiji konvertuje u centimetre. Sva merenja u pikselima su se kroz kompjuterski program konvertovala u milimetre. Mereno je najkraće rastojanje od distalne površine očnjaka do mezijalne površine drugog premolara. Merenja su obavljena tri puta naizmenično, a referentna vrednost je predstavljala srednju vrednost ova tri merenja (Slika 2).

Kako bi se ustanovila preciznost ove metode, uporedo su obavljena merenja i digitalnim nonijusom preciznosti 0,01 mm. Direktnom metodom je izmereno maksimalno rastojanje od distalne površine očnjaka do mezijalne površine drugog premolara. Ova merenja su obavljena za svaki postekstrakcioni prostor tri puta naizmenično. Referentna vrednost je predstavljala srednju vrednost ova tri merenja.

## REZULTATI

Prilikom merenja efikasnosti elastičnog lanca korišćena je metoda fotogrametrije. Testom za višestruka poređenja (Tukey test) testirano je da li postoji razlika između svih vremenskih intervala u kojima je prostor između zuba meren ovom metodom. Ovaj test je pokazao da statistički značajna razlika postoji između svih vremenskih intervala. Prosečno rastojanje između zuba smanjuje se tokom vremena, a prosečan razmak

postekstrakcionog prostora na početku merenja ( $T_1$ ) bio je  $4,03 \pm 1,44$  mm, dok je na poslednjem merenju ( $T_6$ ) iznosio  $0,44 \pm 0,57$  mm (Tabela 1).

Primenom jednofaktorske analize varijanse ponovljenih merenja (Repeated Measure ANOVA) ispitano je da li je došlo do statistički značajne promene u prosečnim vrednostima postekstrakcionih prostora kada se koristi metoda elastičnog lanca merena fotogrametrijom. Prosečne vrednosti merene su u šest vremenskih intervala i utvrđena je statistički značajna promena u prosečnim razmacima postekstrakcionih prostora tokom šest meseci (Vilksova lambda = 0,019, F = 103,98, p = 0,000). Ispitano je i koliki je uticaj elastičnog lanca kao mehanizma za zatvaranje postekstrakcionih prostora. Vrednost Vilksove lambda od 0,01 – mali uticaj, 0,06 – umeren uticaj i 0,14 – veliki uticaj i dobijena  $\eta^2$  koja iznosi 0,98 ukazuju na veoma veliki uticaj elastičnog lanca kao mehanizma zatvaranja postekstrakcionog prostora (Tabela 2).

Grafičkim prikazom je predstavljeno smanjivanje prosečnih vrednosti postekstrakcionih prostora merenih metodom fotogrametrije, pod dejstvom elastičnog lanca (Slika 3).

Kontrolna merenja su obavljena direktnom metodom pomoću digitalnog nonijusa. Prosečan razmak postekstrakcionog prostora na početku merenja ( $T_1$ ) iznosio je  $4,14 \pm 1,47$  mm, a na kraju ( $T_6$ )  $0,46 \pm 0,59$  mm (Tabela 3).

Utvrđena je statistički značajna promena u prosečnim razmacima postekstrakcionih prostora tokom šest meseci (Vilksova lambda = 0,006, F = 322,06, p = 0,000). Ispitano je i koliki je uticaj elastičnog lanca kao mehanizma zatvaranja prostora među zubima. U ovom slučaju dobijena  $\eta^2$  iznosi 0,99, što ukazuje na veoma veliki uticaj elastičnog lanca kao mehanizma smanjenja prostora među zubima (Tabela 4).

Na Slici 4 grafički su prikazane prosečne vrednosti širine postekstrakcionog prostora, odnosno maksimalnog rastojanja među zubima kod upotrebe elastičnog lanca, merene digitalnim kaliperom.

## DISKUSIJA

Pokazalo se da među kliničarima klizna mehanika predstavlja najčešće korišćenu metodu za zatvaranje postekstrakcionog prostora [13]. Mogućnost brze i jednostavne reaktivacije uz minimalno savijanje žice i uštedu vremena su prednosti zbog kojih klizni mehanizam predstavlja metodu izbora u toku terapije zatvaranja postekstrakcionih prostora [14]. Rezultati istraživanja koje su u Brazilu sprovedli Monnini i saradnici potvrđuju da većina specijalista (63,81%) preferira tehniku zasnovanu na kliznoj mehanici, dok su elastični lanci među najviše korišćenim metodama [2]. U sličnoj studiji u Velikoj Britaniji došli su do rezultata da se omče praktično ne koriste za zatvaranje prostora, a klizna tehnika je korišćena u 98% slučajeva [3].

Chitra i Prakash su analizirali upotrebu fotogrametrije u ortodontskoj dijagnostici i planiranju terapije. Ustanovili su da se okluzalna fotogrametrijska analiza može koristiti kao dodatak analizi studijskih modela i za procenu napretka lečenja. U slučajevima kada se koriste aparati za širenje, fotogrametrijsko merenje interkaninog rastojanja, prednje i zadnje širine mogu se periodično koristiti za kvantitativno praćenje da bi se utvrdila promena u toku lečenja [12]. Mogu se takođe primeniti i za merenje meziodistalne dimenzije zuba i u izračunavanju Boltonove



nepodudarnosti, kao i za planiranje korekcije odstupanja od srednje linije [13].

Rezultati ovog istraživanja pokazuju da se postekstrakcioni prostori zatvaraju prosečno za 1,00 mm mesečno kada su merenja obavljena fotogrametrijom. Kontrolna merenja digitalnim kaliperom daju prosečne vrednosti od 1,02 mm mesečno. I jedna i druga metoda potvrđuju veliku efikasnost elastičnih lanaca kod zatvaranja postekstrakcionog prostora.

Brojni autori su analizirali zatvaranje postekstrakcionog prostora na različite načine [14, 15]. Kao najjednostavnija metoda i za pacijenta i za terapeuta pokazalo se direktno merenje digitalnim kaliperom. Najveća prednost je u tome što se rezultati merenja dobiju odmah, što može biti od velikog značaja za procenu dosadašnjeg uspeha i planiranja terapije. Upravo ovu metodu su koristili Dixon i saradnici, koji su primenom elastičnih lanaca kod 10 pacijenata utvrdili da se prostor zatvara za 0,58 mm mesečno [4]. Slično istraživanje su sproveli Chaudhari i Tarvade posmatrajući zatvaranje postekstrakcionih prostora kod 20 pacijenata. U toku četiri meseca merenja su izvršena pomoću digitalnog kalipera od vrha kvržice na očnjaku do vrha meziobukalne kvržice na prvom stalnom molaru, pri čemu su ustanovili da se ta vrednost smanjuje za 0,62 mm mesečno [16]. Direktno merenje su koristili i Kanuru i saradnici kada su ispitivali iznos zatvaranja prostora pomeranjem očnjaka koristeći četiri različita elastična lanca tokom šest sedmica. Merili su rastojanje od kukice bravice na očnjaku do kukice tube na prvom molaru. Nakon tri sedmice izmerene vrednosti za zatvaranje prostora su iznosile od 0,75 mm do 1,12 mm, dok su posle šest sedmica te vrednosti iznosile od 1,47 mm do 2,07 mm [17]. Međutim, najveći nedostatak ove metode je u pravilnom pozicioniranju krakova kalipera, jer se merenje obavlja u ograničenom prostoru u vlažnoj sredini, pa se može desiti da zbog toga dođe do pogrešnih rezultata.

Indirektna merenja podrazumevaju uzimanje otisaka na kontrolnim pregledima, što omogućava ortodontu veći komoditet za analizu i merenje. Ovu metodu su koristili Talwar i Bath, koji su takođe ispitivali efikasnost elastičnih lanaca. Otisci su uzeti na početku i na kraju posmatranog perioda od 12 sedmica. Merenje su se obavljala na studijskim modelima od vrha kvržice na očnjaku do vrha meziobukalne kvržice na prvom stalnom molaru. Prosečne vrednosti su iznosile  $1,62 \pm 0,14$  mm mesečno [18]. Fang i saradnici su sproveli slično istraživanje, ali su se merne tačke nalazile na vrhu kvržice očnjaka i sredini centralne fisure drugog premolara, dok se prostor zatvarao za 0,52 mm mesečno [19].

Sabrina i saradnici su ispitivali zatvaranje postekstrakcionih prostora kod samoligirajućih i konvencionalnih bravica pomoću elastičnog lanca kod 11 pacijenata tokom osam sedmica. Na kontrolnim pregledima su uklanjani lukovi, a otisci su se uzimali preko bravica koje su bile zaštićene voskom. Merenja

su se vršila indirektno na dobijenim studijskim modelima, od distalne površine očnjaka do mezijalne površine drugog premolara pomoću digitalnog kalipera. Prosečna vrednost za konvencionalne bravice je iznosila 0,75 mm, a za samoligirajuće 0,48 mm mesečno [20].

Sličnu split-mouth studiju je sproveo i Mezomo sa saradnicima poredeći konvencionalne i samoligirajuće bravice, a kao klizni mehanizam elastične lance. Na mesečnim kontrolama su uzimani otisci, a merenja su izvršena indirektnom metodom sa digitalnim nonijusom. Rezultati su pokazali da se zatvaranje prostora konvencionalnim bravicama odvija brzinom od 0,84 mm mesečno, dok je za samoligirajuće bravice ova vrednost iznosila 0,90 mm mesečno [21]. Najveći nedostatak indirektnog merenja je u tome što se produžava vreme kontrolnog pregleda, a tome još više može da doprinese nehotično odlepljivanje bravica, što zahteva dodatno planiranje vremena.

Bokas i Woods su posmatrali zatvaranje 12 postekstrakcionih prostora kliznom mehanikom primenom elastičnih lanaca. Kontrolni pregledi su obavljani u intervalima od 28 dana, i na njima su uzimani otisci za studijske modele koji su zatim skenirani. Merenja su izvršena na digitalnim fotografijama dobijenim okluzalnim skeniranjem pomoću odgovarajućeg softvera. Rezultati pokazuju da su elastični lanci zatvarali prostore za 1,68 mm mesečno [22]. Skeniranje modela i analiza njihovih 3D replika pruža ortodontu mogućnost merenja u tri dimenzije, a softverska manipulacija omogućava praćenje i predviđanje rezultata terapije. Međutim, pravilno analiziranje i merenje skeniranih modela zahteva uvežbanost i dobro poznavanje mogućnosti koje pruža softver.

Kao i prethodne metode, fotogrametrija ima svoje prednosti i nedostatke. Prednost je pre svega u tome što se izbegava uzimanje otisaka. Zapis koji se dobije ovom metodom je u boji i verno oslikava i područje merenja, ali i strukture oko njega. Još jedna prednost koju nose digitalne fotografije je to što se snimak može odmah ponoviti ukoliko nije zadovoljavajući, a merenja obaviti kasnije bez žurbe. Pored određene neprijatnosti kod fotografisanja, najveća mana ove metode je nedostatak treće dimenzije. Zato je neophodno da uslovi fotografisanja budu standardizovani.

## ZAKLJUČAK

Elastični lanac se pokazao kao veoma efikasan mehanizam za zatvaranje postekstrakcionog prostora, a fotogrametrija kao jednostavna i precizna metoda za praćenje rezultata terapije. S obzirom na to da je razlika u odnosu na merenja digitalnim kaliperom minimalna, fotogrametrija se može rutinski primenjivati u svakodnevnoj praksi.